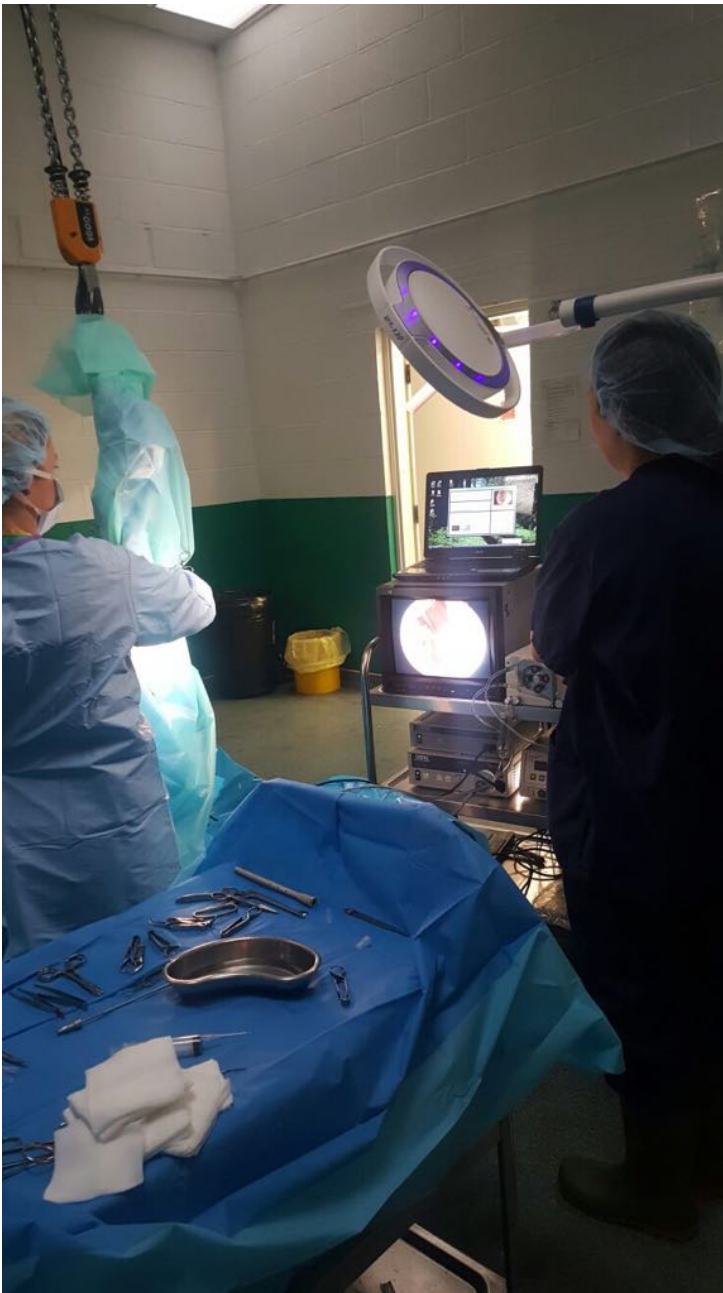

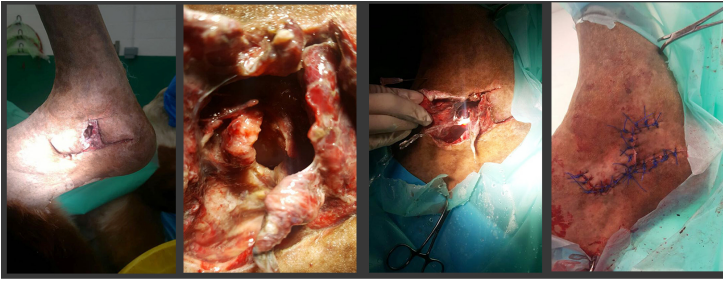
## Dotty- Equine Referral Clinic



Please note, this post contains graphic content that some readers may find disturbing.

'Dotty', a 5 year old pony was referred to our [Equine Referral Clinic](#) for treatment of a severe injury of her right hock. Poor Dotty had been kicked by her field companion, leading to a large flap of skin, under which was an enormous communication with her hock joint, leading to life-threatening infection of the joint.

Unfortunately for the horse, antibiotic penetration of joints is poor, and bacteria find very clever ways of hiding in a horse's joint, meaning that they can rarely be successfully managed with medication alone.



The best way to combat these infections is to surgically flush out the joint, within a 24-hour period. At Oakhill, we use an arthroscope (camera), to visualise the joint surface via keyhole incisions. During this procedure, any dirt or hair can be seen and therefore removed. At the same time we flush up to 10 litres of sterile saline to flush out the infection. Dotty underwent this procedure, and the complex skin flap was then closed over the exposed joint very carefully, in multiple suture layers. Intensive post-operative antibiotics into her vein and her joint following surgery ensured a successful outcome was reached for this lovely pony. She is now enjoying a normal life back at home with her owners!